

Inguinal Canal Hydatidosis Presenting as Irreducible Inguinal Hernia: A Case Report

Nasser Malekpour-Alamdari¹, Barmak Gholizadeh¹, Fereshteh Kimia²

¹ Assistant Professor, Department of Surgery, School of Medicine AND Shahid Modarres Medical Center, Shahid Beheshti University of Medical Sciences, Tehran, Iran

² Resident, Department of Anesthesiology, School of Medicine AND Shahid Modarres Medical Center, Shahid Beheshti University of Medical Sciences, Tehran, Iran

Received: 13 Feb. 2017; Received in revised form: 26 Mar. 2017; Accepted: 12 Apr. 2017

Abstract

Background: Hydatidosis is a parasitic infestation caused by *Echinococcus granulosus*. This tapeworm commonly affects liver and lungs. Its diagnosis in unusual locations may be make some challenges for practicing physicians.

Case Report: A 45-year-old man presented with bulging and discomfort in the right lower quadrant from 2 years ago. Computed tomographic examination showed an oval cyst measuring about 7 cm × 15 cm in the inguinal area. In the operating room, after sealing the area with appropriate amounts of gauze soaked in silver nitrate the cyst punctured and clear fluid aspirated from the cyst; then, the cyst was sterilized using silver nitrate and opened. Daughter cysts were extracted from the cyst, the cyst was carefully freed from surrounding structures, and total excision of the cyst was performed. Post-operative period was uneventful, and no recurrence was encountered during the 6-month follow-up period.

Conclusions: In this case, we present a patient with swelling in the inguinal area, which turns out to be hydatid cyst. To our knowledge, there has been no case of hydatid cyst arising primarily from inguinal canal. Hydatid disease can present with many different symptoms, and in this case, we present one the rare presentations of this disease. So that for a surgeon who works in the endemic areas, it is important to be aware about the varying presentations of the disease so that in the operation room should do required preparations to prevent unwanted serious problems such as spillage of intracystic materials.

© 2017 Tehran University of Medical Sciences. All rights reserved.

Citation: Malekpour-Alamdari N, Gholizadeh B, Kimia F. **Inguinal Canal Hydatidosis Presenting as Irreducible Inguinal Hernia: A Case Report.** *Acad J Surg*, 2017; 4(3): 87-9.

Keywords: Echinococcosis; Inguinal canal; Case report

Introduction

Hydatidosis is a parasitic infestation caused by *Echinococcus granulosus* and rarely by *Echinococcus multilocularis*. The hydatid disease is a public health and economic problem in the middle east, Mediterranean countries and South Asia and far east (1). This tapeworm commonly affects liver and lungs but in some rare instances can involve any other organ in the body such as brain and spleen (2). Its diagnosis in unusual locations may make some challenges for practicing physicians. Furthermore, it is not a known consensus about management of hydatidosis of rare places.

We present a unique case of retroperitoneal hydatidosis which protruded through inguinal canal mimicking large irreducible inguinal hernia.

Case Report

The patient was a 45-year-old man presented to our

university based hospitals clinic complaining from bulging and discomfort in the right lower quadrant from 2 years ago. There was no history of trauma, he was a Shepherd from west Azerbaijan state and had unremarkable medical history. He stated that he had a similar problem on the left inguinal side whom undergone left herniorrhaphy 15 years ago.

On examination, pulse was 82 beats/minute, blood pressure was 123/65 mm Hg, and oral temperature was 36.5 °C. On abdominal physical examination other than previous herniorrhaphy scar on the left side and burning scar on the right side, there was firm, non-pulsatile, slightly tender 4 cm × 10 cm mass in the right inguinal side which was not mobile during straining or coughing. The rest of examination was unremarkable.

Ultrasonography was performed and showed a thin-walled, anechoic, cystic mass in the inguinal canal which was protruded from external ring outside. Computed tomographic examination showed an oval cyst measuring about 7 cm × 15 cm with high

attenuated wall without any attenuation within the cyst. The cyst was located in the inguinal canal there was not any calcification on the cyst wall or any other cystic structure in the abdomen or thorax.

Other laboratories and radiologic examinations were unremarkable. First diagnosis which should be in the top of our list was infected hydatid cyst, but the location and absence of hepatic and pulmonary involvement could compromise this diagnosis. Another differential diagnosis was mesenteric cyst or ovarian cyst herniating through inguinal canal. Due to his pain and discomfort patient was candidate for surgery.

In the operating room, the patient was operated under spinal anesthesia, and classical inguinal incision was preferred, and after going through skin and subcutaneous area, we encountered a large firm hydatid cyst protruding from inguinal canal. After sealing the area with appropriate amounts of gauze, soaked in Silver nitrate the cyst punctured and clear fluid aspirated from the cyst then the cyst was sterilized using Silver nitrate then opened (Figure 1).

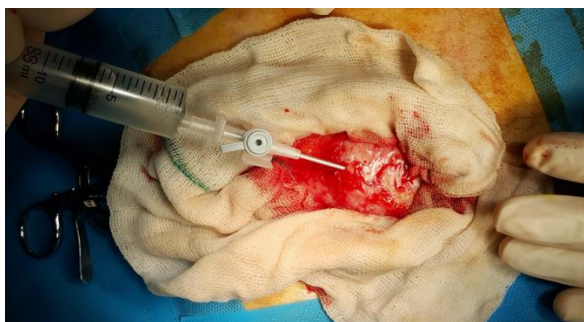

Figure 1. After sealing the operative field with appropriate amounts of Silver nitrate soaked gauze, the cyst punctured and clear fluid aspirated from the cyst

After opening the cyst wall, the typical germinative membrane of a hydatid cyst was identified and extracted (Figure 2). Then, daughter cysts were extracted, and the cyst was carefully freed from surrounding structures, and total excision of the cyst was performed. Further, examination revealed a right indirect inguinal hernia which had been repaired using Modified Bassini method.

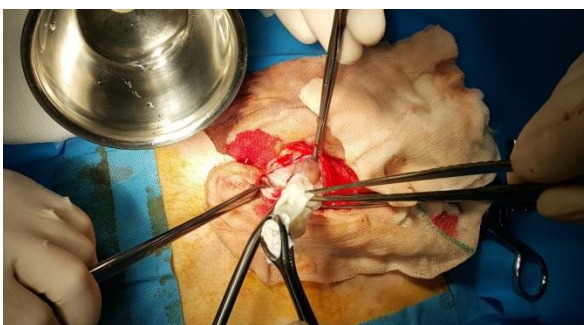


Figure 2. After opening the cyst wall, the typical germinative membrane of a hydatid cyst was identified and extracted

Post-operative period was uneventful, and the patient had full recovery and discharged from hospital with albendazole 10 mg/kg/day for 6 months. Pathologic examination confirmed the diagnosis of hydatid cyst. No recurrence was encountered during the 6-month follow-up period.

Discussion

Hydatid disease is one of the well-known infestations all over the world which is endemic in meditation countries and Middle East and South America (3). This disease is caused by cystic stage of *E. granulosus* larva (1). The most common sites in the body are liver and lungs, but the disease can involve anywhere in the body (4-6). The symptoms of hydatid disease are nonspecific and usually are the result of a mass like lesion and compression of adjacent organs (7,8). Due to high rates of false positive results, blood tests are not helpful in the diagnosis of hydatid cysts (3). The imaging modalities such as ultrasonography and computed tomography (CT) scanning are helpful. Finding such as calcified cyst wall and microcalcifications within daughter cysts and varying fluid densities between cysts and surrounding organs are strongly suggests the diagnosis of hydatid disease. However, these findings are dependent to disease stage, and in some stages of hydatid disease, we may see nothing diagnostic in the imaging. Furthermore, if the cysts were presented in unusual sites the exact diagnosis is difficult, and differential diagnosis is high (9-11). Treatment modality of choice is complete excision of the cyst, but in some cases in which total excision is impossible other modalities such as partial cystectomy or even non-surgical therapies such as medical or puncture-aspiration-injection-reaspiration technique has been proposed (7,12-14).

In this case, we present a patient with swelling in the inguinal area, which turns out to be hydatid cyst. Inguinal canal is one of the rare sites for hydatid cyst. In the literature, there are some case reports with retroperitoneal hydatid disease which presented with symptoms mimicking inguinal hernia, but to our knowledge, there has been no case of hydatid cyst arising primarily from inguinal canal (15,16). The suggested pathophysiology of these problems is hematogenous or lymphatic spread (17). In this case, diagnostic work-up was the same as the other cases, by ultrasonography and CT scan. However, no diagnostic features had been obtained and we had too many other differential diagnoses in mind. Due to this situation, the case was discussed in the multidisciplinary team, and the suggested plan was proceeding to surgery.

In the operating room, it had been prepared all the facility to approach the hydatid cyst, and the operative field was sealed with silver nitrate soaked gauzes. After puncturing the cyst, because of aspiration of clear fluid,

the diagnosis of hydatid cyst was confirmed, and the operation proceeded and total excision of cyst were performed which is the standard treatment for hydatid cyst (14).

After literature review, it has been found some articles about cases with retroperitoneal hydatid cysts presenting with inguinal or scrotal swelling (15,16,18). However, this case is unique in that matter which in this case there is not a retroperitoneal mass protruding through inguinal canal but a mass which had been risen from inguinal canal. Hence, that, this case was a great challenge in the diagnostic and treatment plan.

In conclusion, hydatid disease can present with many different symptoms, and in this case, we present one the rare presentations of this disease. So that for a surgeon who works in the endemic areas, it is important to be aware about the varying presentations of the disease so that in the operation room should do required preparations to prevent unwanted serious problems such as spillage of intracystic materials.

Hence, that, we suggest the diagnosis of hydatid cyst should be suspected especially in endemic regions in all patients presenting with cystic mass like lesion anywhere in the body.

Conflict of Interests

Authors have no conflict of interests.

Acknowledgments

The authors would like to represent their sincere appreciation to all the staff of Shahid Modarres Hospital, for their kind support and cooperation.

References

1. Thompson RC, Lymbery AJ. Echinococcus and hydatid disease. Wallingford, UK: CAB International; 1995.
2. Durakbasa CU, Tireli GA, Sehiralti V, Sander S, Tosyali AN, Mutus M. An audit on pediatric hydatid disease of uncommon localization: Accidence, diagnosis, surgical approach, and outcome. *J Pediatr Surg* 2006; 41(8): 1457-63.
3. Ercetin C, Tukenmez M, Dural C, Poyanli A, Salmaslioglu A, Bilgic B, et al. Primary retroperitoneal hydatid disease mimicking retroperitoneal malignant tumor. *Int J Infect Dis* 2008; 12(4): 402-5.
4. Eolakoglu N, Kukner A, Kara H, Ozan E. Structural changes induced by cadmium chloride and effects of metallothionein on these changes in rat testicular tissue: A light microscopic study. *Turkiye Klinikleri J Med Sci* 2004; 24(3): 201-6.
5. Polat P, Kantarci M, Alper F, Suma S, Koruyucu MB, Okur A. Hydatid disease from head to toe. *Radiographics* 2003; 23(2): 475-94.
6. Kiresi DA, Karabacakoglu A, Odev K, Karakose S. Uncommon locations of hydatid cysts. *Acta Radiol* 2003; 44(6): 622-36.
7. Xiao L, Ryan U, Feng Y. *Biology of foodborne parasites*. Boca Raton, FL: CRC Press; 2015.
8. Sayek I, Tirnaksiz MB, Dogan R. Cystic hydatid disease: Current trends in diagnosis and management. *Surg Today* 2004; 34(12): 987-96.
9. Pedrosa I, Saiz A, Arrazola J, Ferreiros J, Pedrosa CS. Hydatid disease: Radiologic and pathologic features and complications. *Radiographics* 2000; 20(3): 795-817.
10. von Sinner WN. New diagnostic signs in hydatid disease; Radiography, ultrasound, CT and MRI correlated to pathology. *Eur J Radiol* 1991; 12(2): 150-9.
11. Gossios KJ, Kontoyiannis DS, Dascalogiannaki M, Gourtsoyiannis NC. Uncommon locations of hydatid disease: CT appearances. *Eur Radiol* 1997; 7(8): 1303-8.
12. Zaharie F, Bartos D, Mocan L, Zaharie R, Iancu C, Tomus C. Open or laparoscopic treatment for hydatid disease of the liver? A 10-year single-institution experience. *Surg Endosc* 2013; 27(6): 2110-6.
13. Nahmias J, Goldsmith R, Soibelman M, el-On J. Three- to 7-year follow-up after albendazole treatment of 68 patients with cystic echinococcosis (hydatid disease). *Ann Trop Med Parasitol* 1994; 88(3): 295-304.
14. Yagci G, Ustunoz B, Kaymakcioglu N, Bozlar U, Gorgulu S, Simsek A, et al. Results of surgical, laparoscopic, and percutaneous treatment for hydatid disease of the liver: 10 years experience with 355 patients. *World J Surg* 2005; 29(12): 1670-9.
15. Uysal S, Tuncbilek I, Gokharman D, Kacar M, Birincioglu P, Kosar U. Female genitalia hydatidosis herniating to the inguinal canal. *Abdom Imaging* 2005; 30(5): 623-5.
16. Spiliotis JD, Kakkos SK, Petsas T, Siablis D, Androulakis JA. Inguinal swelling: A rare a presentation of retroperitoneal hydatidosis. *Eur J Surg* 1999; 165(1): 75-6.
17. Elton C, Lewis M, Jourdan MH. Unusual site of hydatid disease. *Lancet* 2000; 355(9221): 2132.
18. Khan RA, Wahab S, Chana RS, Fareed R. Isolated retroperitoneal hydatid cyst in a child: a rare cause of acute scrotal swelling? *J Pediatr Surg* 2010; 45(8): 1717-9.