

Placenta Percreta in the Uterus Fundus at the Second Trimester: A Case Report

Zohreh Kazemi¹, Khadijeh Rezaie-Kahkhay², Zahra Anfasi³

¹ Department of Gynecologic Oncology, School of Medicine AND Research Development Unit Taleghani Hospital, Shahid Beheshti University of Medical Sciences, Tehran, Iran

² Department of Gynecologic Oncology, School of Medicine AND Amir Al-Momenin Hospital, Zabol University of Medical Sciences, Zabol, Iran

³ Gynecologist, Atieh Hospital, Tehran, Iran

Received: 19 Jan. 2017; Received in revised form: 15 Feb. 2017; Accepted: 10 Apr. 2017

Abstract

Background: Placenta percreta is a rare complication of pregnancy with catastrophic outcomes for both mother and fetus. Abnormal placental attachment due to inadequate deciduas formation between trophoblast and myometrium is the main histological finding.

Case Report: We present a case of placenta percreta in a 25-year-old woman accompanied by spontaneous uterine rupture at 25th week of gestation. In view of clinical symptoms and laboratory findings, the patient underwent laparotomy with a primary diagnosis of acute abdomen. We found no predisposing factor for abnormal placentation. As our patient wished to remain fertile, a successful uterine repair was performed.

Conclusions: Histological assessment of the uterus showed placenta percreta. It is very rare for placenta percreta to cause uterine rupture in the second trimester, especially in a patient without any risk factors.

© 2017 Tehran University of Medical Sciences. All rights reserved.

Citation: Kazemi Z, Rezaie-Kahkhay K, Anfasi Z. **Placenta Percreta in the Uterus Fundus at the Second Trimester: A Case Report.** *Acad J Surg*, 2017; 4(2): 61-3.

Keywords: Placenta percreta; Pregnancy; Uterine rupture; Acute abdomen

Introduction

Uterine rupture caused by placenta percreta is a rare complication of the pregnancy. This condition is not usually among first differential diagnosis of a pregnant woman presenting with acute abdomen (1). Risk factors associated with placenta percreta are previous cesarean section, multiple pregnancies, a history of manual placenta extraction, advanced maternal age, multiparity, placenta previa, dilatation and curettage, history of myomectomy, endometritis, repetitive abortions, and uterine malformations (2). The diagnosis of placenta percreta is made clinically as other more common differential diagnosis such as acute appendicitis, ovarian torsion, urinary tract infection, and peritonitis are ruled out. The definite diagnosis is based on a histopathological study of uterine rupture site and confirmation of the absence of the placenta basal plate and the presence of trophoblastic tissue in the myometrium and/or the uterine serous (3). To localize abnormal implantation of trophoblastic tissue in uterus wall, ultrasound imaging may be helpful as it can show fluid retention in cul-de-sac. Diagnostic laparoscopy can be used as both diagnostic and therapeutic tool, although, laparotomy or more aggressive surgical procedures may be needed (3). Treatment strategies vary from cesarean hysterectomy

to cesarean section without placental extraction, and the most frequent treatment is hysterectomy because of life-threatening potential of such cases (2).

Case Report

A 25-year-old G2P1 was admitted to the Department of Gynecology, Amir Al-Momenin hospital, Zabol University of Medical Sciences, Zabol, Iran. She had a complaint of severe abdominal pain on her 25th week of gestation. The pain initiated 2 hours before admission in the right lower abdomen. She described her pain as constant and unremitting. It was worsening in nature and associated with nausea and vomiting. There were no characteristics that aggravate or alleviate the pain.

Patient's history for previous abdominal surgery was negative. Her past medical history was insignificant, and there was no allergy reported.

Her first pregnancy was 8 years before surgery and resulted in fetal death due to prematurity. Hence, patients were so eager to have child.

The present gravidity was occurred spontaneously and detected at 7th week of gestation. Her abdominal ultrasound was reported to be normal in all checkups.

Physical examination suggested tenderness in the whole abdomen and the most tender site was in the right lower quadrant.

Corresponding Author: Zohreh Kazemi

Taleghani Hospital, Chamran Highway, Yaman St, Shahid Arabi St, Tehran, Iran
Tel: +98 9153414404/ Fax: +98 21 88712038, E-mail: zohrekazemi@sbmu.ac.ir

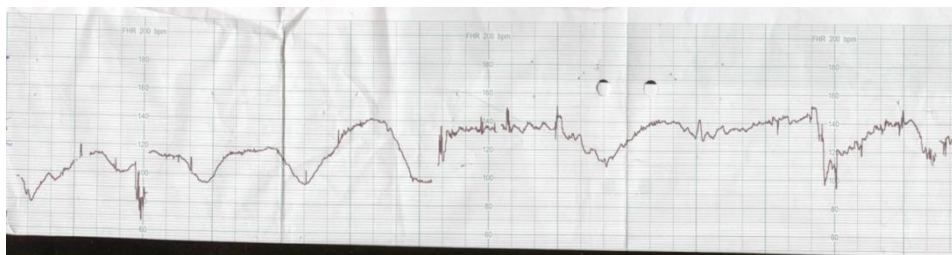


Figure 1. Nonstress test indicating prolonged fetal heart deceleration

Bowel sounds and urination were normal. The oral temperature was 37 centigrade, and there was no tachycardia or tachypnea detected in the initial examination at admission. Blood pressure was in normal ranges. The gynecologic examination of vulva and vagina was not significant. The cervix was long and rigid. Normal secretions were found and no vaginal bleeding was detectable. Unfortunately, abdominal ultrasound could not demonstrate the exact pathology and demonstrated a normal pregnancy with no fluid in the cul-de-sac. 4 hours after admission nonstress test frequently showed prolonged fetal heart deceleration (Figure 1) and our patients developed tachycardia at 120 beats/minutes. Furthermore, her physical examination was suggestive for severe generalized abdominal tenderness. Laboratory results showed a decline in hemoglobin level from 10 mg/dl to 9.2 mg/dl. Based on the described symptoms and the clinical findings, urgent cesarean performed under spinal anesthesia with a primary diagnosis of occult placental abruption. Perioperative antibiotics were given. We used Pfannenstiel surgical incision to open the abdomen as our primary diagnosis was occult placental abruption. When peritoneum was incised, the whole cavity was full of blood, and about 1500 cc clotted blood was removed from peritoneal cavity. The uterus appeared normally developed for the 25th week of gestation with normal ovaries and tubes; uterus was palpated because spontaneous uterus rupture was suspected, but uterus palpation was not indicative for it. However, fetal distress, obligated surgeons to cut the uterus infant was delivered by low segmental uterus incision. Infant resuscitation was begun immediately after birth. When the fetus was pulled out, it was demonstrated that there was an oozing site on uterus fundus from a dilated and tortuous vessel. It seems that vital sign stability in contrast to severe blood loss can be explained by patient's young age and gradual oozing in long-term period. Furthermore, we should consider that circulatory volume increase during pregnancy.

All the blood was removed by suction. During operation, we found that placenta has attached to uterine fundus and extended through serous but had not involved any of abdominopelvic organs. There were dilated and tortuous vessels on rupture site, bleeding through lesion.

Hence, placenta percreta was suspected which was

confirmed later by histopathological assessment (Figure 2).

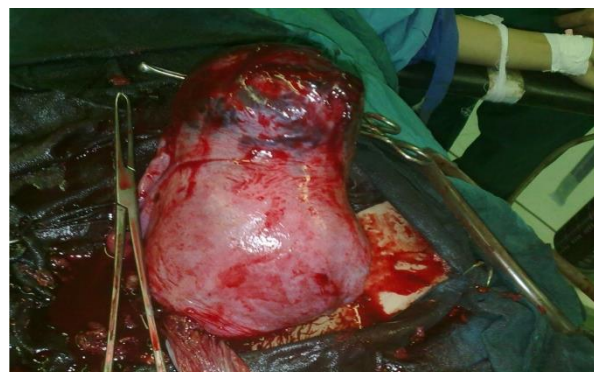

Figure 2. Pregnant uterus with a placenta percreta at fundus

Patient desired to save her uterus as she was obsessed to have children, we decided to repair uterus and wedge resection of fundus was performed. Post-operative hemoglobin level was 6 g/dl therefore 3 units of packed cells were administered intravenously. The patient was admitted to ICU postoperatively for 2 days. She recovered uneventfully and was discharged 4 days later in a healthy condition.

Histological study showed placenta percreta penetrating the uterus up to the serous. The fetus was not viable and passed away at the admission day..

Discussion

Placenta percreta, the rarest and most severe form of placenta accreta, occurs when placenta extend through the entire myometrial layers and uterine serous (2). Placenta accreta occurs approximately in 1 out of 7000 pregnancies (3). Of these, about 75-80% are placenta accreta, about 17% are placenta increta, and remaining are placenta percreta (1). Although the overall incidence of placenta percreta is extremely low, growing numbers of cesarean deliveries in the past few years resulted in higher rates of this disorder. A deficit in decasualization may contribute to the development of abnormal placentation. In comparison to the rest of uterine cavity, the lower uterine segment proximal to the cervical canal contains relatively less decasualized tissue. Similarly, cesarean delivery, uterine curettage or hysteroscopy surgery, myomectomy, endometrial

ablation, and uterine artery embolization may result in localized decidua defects and consequently abnormal placentation. Thus, abnormal placentation can be defined as aberrant placentation in fundus of uterus in a patient with no history of previous surgical intervention. We did not find any etiologies for abnormal placentation in our patient. Therefore, we assume abnormal or excessive trophoblast invasion to uterine fundus may explain the pathophysiology of aberrant placentation. Predisposing factors for abnormal placentation according to a large matched case-control study were prior cesarean section, age <35 years, placenta previa, increased parity over 5 times, history of abortion, prior curettage. Among these factors, only advanced maternal age, prior cesarean section, and history of placenta previa were statistically significant (4). Placenta percreta without any risk factors has been reported scarcely. Sonin (5) reported placenta percreta in uterine fundus in a 30-year-old nulliparous with no significant medical or surgical history. Angelidou et al. (6) patient was a 45-year-old woman with placenta percreta in uterine fundus. As there were not any known risk factors in these cases, investigators were not able to rationalize the presence of abnormal placentation. Surgical interventions have been suggested as the first line for the treatment of placenta percreta; as hysterectomy was chosen in 93% of all cases. Conservative management is exclusively used in rare setting of the adjacent organ involvement such as bowel or bladder. Due to increased risk of massive hemorrhage, chemotherapeutic agents, especially Methotrexate, have been used with success in several patients. Furthermore, transcatheter embolization has been utilized (5). Legro et al. (7) reported a successful non-surgical treatment of placenta percreta by Methotrexate chemotherapy in a patient who was able to carry a normal pregnancy 2 years later. In contrast to this study, Butt et al. (8) declared that conservative management with methotrexate chemotherapy is unsuccessful and would result in subsequent hysterectomy because of postpartum bleeding. To find an accurate approach to patients with anterior placenta percreta based on homeostatic procedures and uterine repair, Palacios Jaraquemoda et al. (9) surveyed 68 patients. The uterus of 50 patients with anterior placenta percreta was repaired surgically, and 10 pregnancies were reported after the repair, which was terminated by uncomplicated cesarean delivery. Based on these findings, it would be reasonable to assume that a functional and anatomical uterine repair will lead to successful pregnancy. Our case demonstrated that placenta percreta is a catastrophic complication should be considered in both pregnant women with predisposing factors (multiple pregnancies, prior cervical dilatations and curettages, and uterine scars) and those without any risk factors

presenting with acute abdomen or shock. In a non-emergency setting, if there is no evidence of more common differential diagnosis, laparoscopic investigation of peritoneum may help to confirm the diagnosis. Hysterectomy is the only lifesaving intervention in patients with severe internal bleeding (10). In a non-severe life-threatening setting with small uterine rupture, surgical uterine repair might be feasible for those patients who have a tendency to remain fertile.

Conflict of Interests

Authors have no conflict of interests.

Acknowledgments

The authors would like to express their sincere gratitude to all the staff of Taleghani Hospital, whose kind supports enabled us to run this study.

References

1. Binkowska M, Ciebiera M, Jakiel G. Placenta accreta: Review and 3 case reports. *Ginekol Pol* 2015; 86(5): 396-400.
2. Suwannarurk K, Pongrojpraw D, Manusook S, Suthiwartnarueput W, Bhamarapratana K. Spontaneous uterine rupture at non-cesarean section scar site with placenta percreta in the second trimester: A case report. *J Med Assoc Thai* 2014; 97(Suppl 8): S208-S212.
3. Hornemann A, Bohlmann MK, Diedrich K, Kavallaris A, Kehl S, Kelling K, et al. Spontaneous uterine rupture at the 21st week of gestation caused by placenta percreta. *Arch Gynecol Obstet* 2011; 284(4): 875-8.
4. Wu S, Kocherginsky M, Hibbard JU. Abnormal placentation: Twenty-year analysis. *Am J Obstet Gynecol* 2005; 192(5): 1458-61.
5. Sonin A. Nonoperative treatment of placenta percreta: Value of MR imaging. *AJR Am J Roentgenol* 2001; 177(6): 1301-3.
6. Angelidou S, Assimaki M, Gritsi-Gerogianni N, Katsanoulas C, Kopatzidis H, Mouloudi H. Placenta percreta with bladder involvement and profound haemorrhage: A report of two cases and short review of the literature. *Greek e J Perioper Med* 2009; 7: 114-21.
7. Legro RS, Price FV, Hill LM, Caritis SN. Nonsurgical management of placenta percreta: A case report. *Obstet Gynecol* 1994; 83(5 Pt 2): 847-9.
8. Butt K, Gagnon A, Delisle MF. Failure of methotrexate and internal iliac balloon catheterization to manage placenta percreta. *Obstet Gynecol* 2002; 99(6): 981-2.
9. Palacios Jaraquemada JM, Pesaresi M, Nassif JC, Hermosid S. Anterior placenta percreta: Surgical approach, hemostasis and uterine repair. *Acta Obstet Gynecol Scand* 2004; 83(8): 738-44.
10. Henrich W, Fuchs I, Ehrenstein T, Kjos S, Schmider A, Dudenhausen JW. Antenatal diagnosis of placenta percreta with planned in situ retention and methotrexate therapy in a woman infected with HIV. *Ultrasound Obstet Gynecol* 2002; 20(1): 90-3.