

## Unveiling the Hidden Peril: A Rare Case of Gossypiboma in an Elderly Woman

Vinay H G, Naveen N, Ramprashanth M P

Vamshodaya Hospital, Kolar, Karnataka, India

Received: 31-05-2023; Received: 22-06-2023; Accepted: 29-08-2023

### Abstract

**Background:** Revolutionary developments in the surgical field have led to a comparative reduction in surgery-associated complications than in the past. However, some complications, which directly indicate surgeon's negligence, should not be underestimated. Gossypibomas, a rare but horrifying complication of surgeries, occur when cotton foreign bodies are retained in the patient and are only discovered after long periods of time.

**Methods:** A 46-year-old diabetic anemic female, with a previous history of operative management for cancer of the cervix (stage IA2), presented with features suggesting sub-acute intestinal obstruction.

**Results:** Contrast Enhanced Computed Tomography (CECT) of the abdomen revealed a linear hyper-attenuating string-like structure in the distal bowel loop, suggesting a Retained Foreign Body. The patient was immediately taken up for exploratory laparotomy, and the retained foreign body was removed.

**Conclusions:** Although the diagnosis of Gossypibomas can be challenging at times, it is imperative to manage patients with this rare complication swiftly and precisely to prevent permanent future disabilities. Young surgeons should be made aware of the legal consequences of such a dreaded complication and should anticipate the diagnosis in bizarre surgical circumstances.

**Citation:** Vinay H.G., Naveen N., Ramprashanth M.P. **Unveiling the Hidden Peril: A Rare Case of Gossypiboma in an Elderly Woman.** *Acad J Surg*, 2023; 6(1): 24-28.

**Keywords:** Medico-legal, Surgical Complication, Foreign Body

### Introduction

Gossypiboma refers to a surgical complication where cotton gauze, a foreign body, is left in situ post-operatively. It is a rare but serious complication of surgeries with vast legal consequences. Although such a complication is avoidable, the possibility of a patient ending up with such a complication is never nil. Since gossypibomas are not anticipated, they are also the most frequently misdiagnosed, leading to radical surgeries being performed on the patient later. Therefore, gossypibomas should be considered in post-operative patients with unusual symptoms or unresolved problems [1]. They raise questions about the safety standards of surgeries being performed, especially in developing countries like India, where relatively more human errors tend to occur. This text discusses a case report of gossypiboma found in an

elderly female post hysterectomy.

### Clinical Description

A 46-year-old diabetic female presented to the hospital with intermittent vomiting, abdominal pain, and loose stools for a week. On examination, the patient was dehydrated and anaemic. The abdomen was distended, with increased bowel sounds. Systemic examination of the respiratory system, cardiovascular system, and central nervous system were normal. She had previously been diagnosed with cervical carcinoma stage IA2, for which she underwent radical hysterectomy with two cycles of adjuvant radiotherapy in September and October 2021. Clinical features were suggestive of subacute intestinal obstruction, and the patient was admitted for further management.

\* Corresponding author: Dr. Vinay H G

Department of General Surgery, Vamshodaya Hospital, Kolar, Karnataka

Tel.: (+91) 9611771715 Email: vinay\_1771@yahoo.co.in



### Management and Outcome

The patient underwent CECT (contrast-enhanced computed tomography) of the abdomen on 21-03-2022 (Fig 1), which showed an enlarged Riedel's lobe of the liver, a grossly distended gall bladder measuring 10.2 cm, with intramural sludge, and more importantly, a linear hyper attenuating string-like structure in the distal bowel loop (suggesting a RFB) and significantly dilated small bowel loops.

The patient was immediately taken up for exploratory laparotomy under general anaesthesia on 25-03-2022. On opening the abdomen via a midline incision (Fig 2), dense interbowel adhesions

with cocooning of the bowel (Fig 3), inflamed and thickened gall bladder wall with omental adhesions, and interbowel fistula involving the proximal ileum were seen. A C-arm X-ray of the suspected part of the bowel was done to localise the RFB (Fig 4). A retained surgical cotton (Fig 5, Video 1) of size 20cm by 20cm was removed through the ileal lumen via enterotomy. The ileal fistula was dismantled, and the fistulous opening was closed. Adhesiolysis was done. Peritoneal lavage was given, and the abdomen was closed. A part of the peritoneum was sent for histology, which was reported as an inflammatory reaction. Post-operatively, the patient was started on the combination of piperacillin and tazobactam (4.5g)

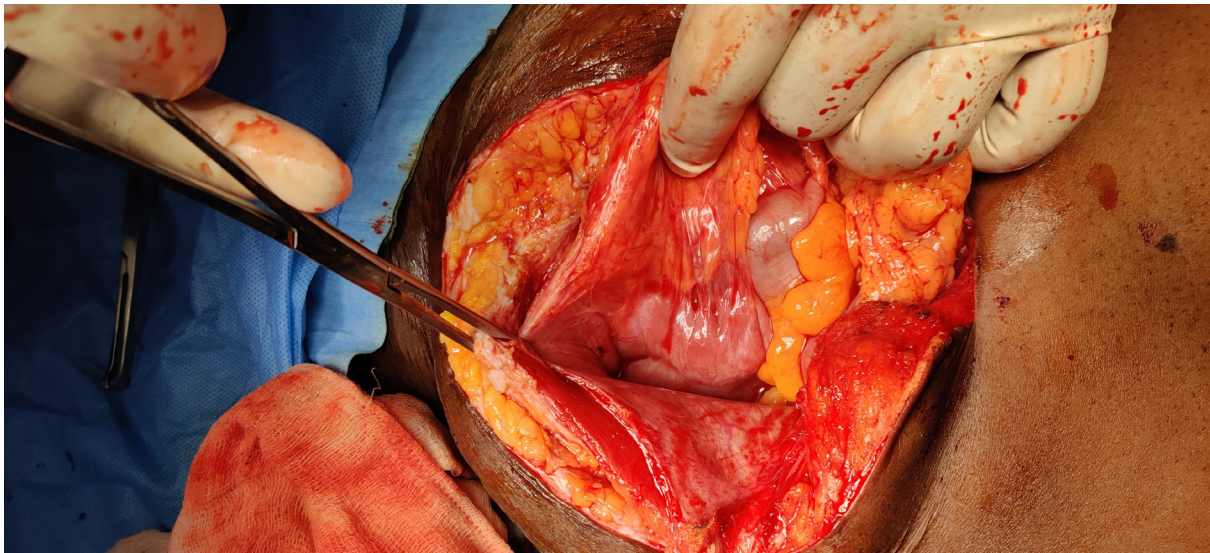

Figure 1:

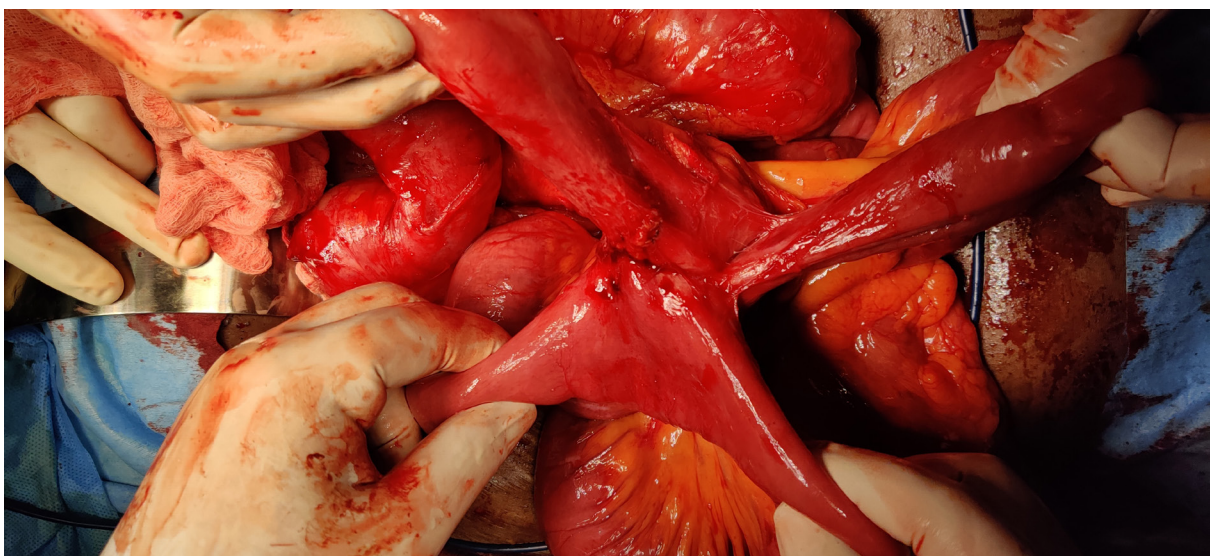

Figure 2:



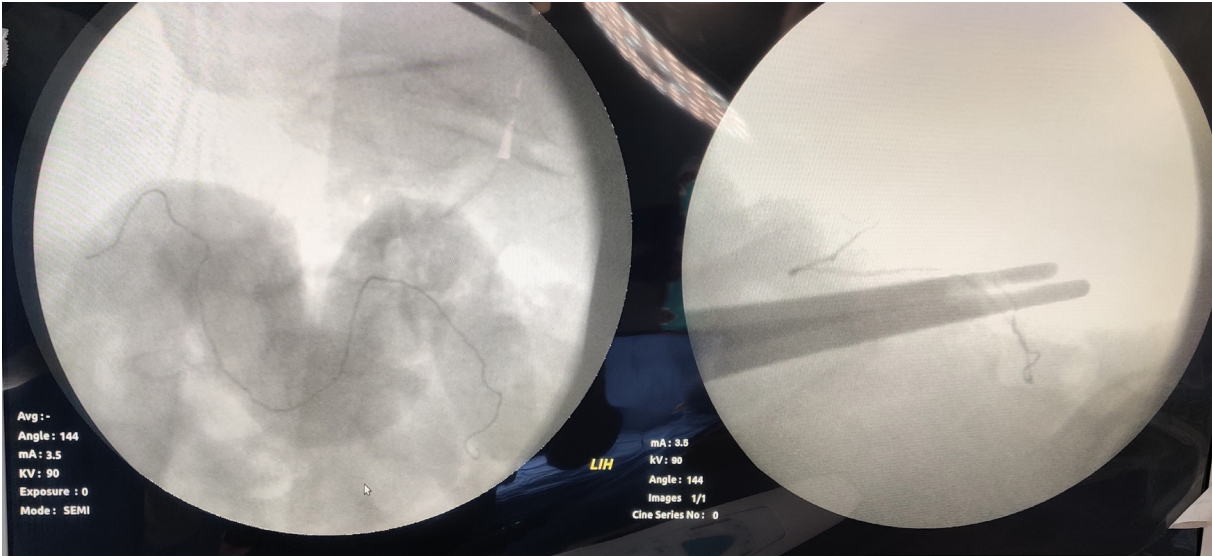


Figure 3:

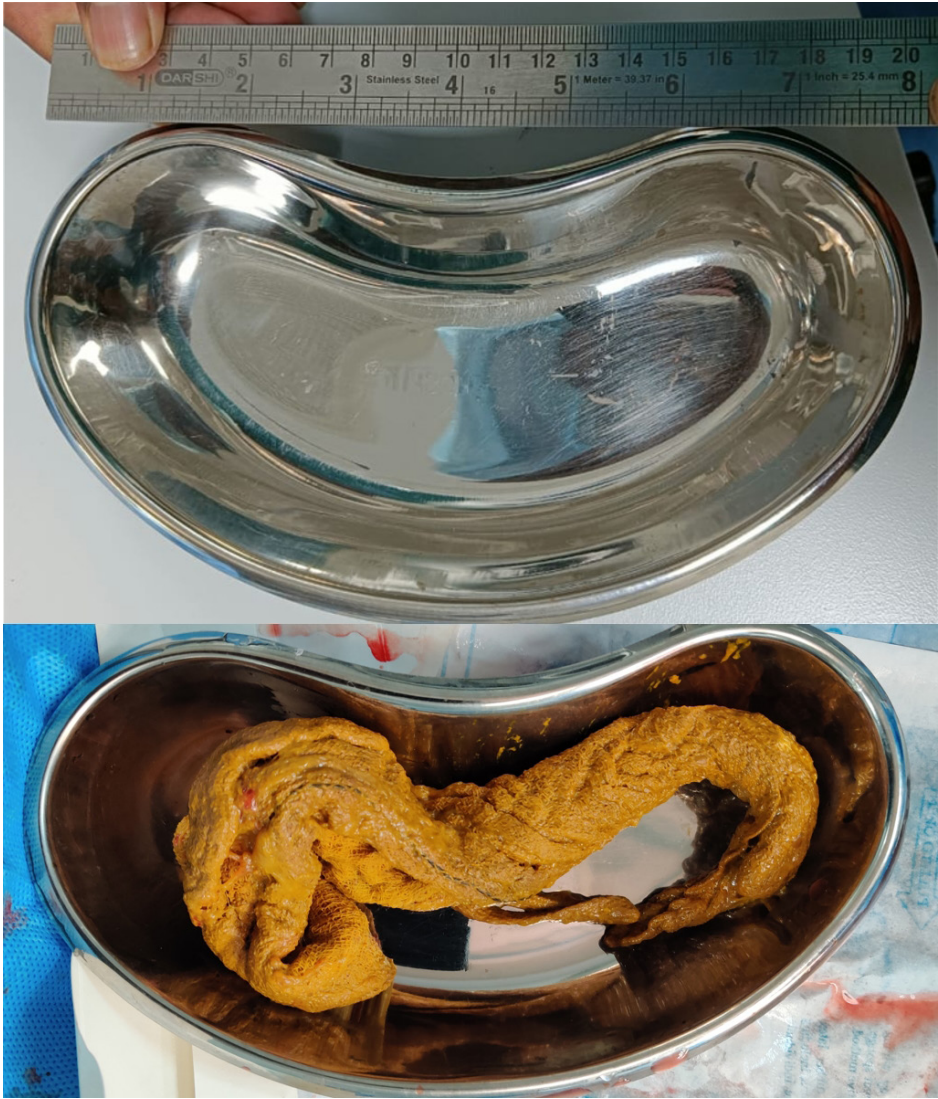

Figure 4:

twice daily, injection metronidazole 500 mg thrice daily, injection paracetamol 1g thrice daily, injection enoxaparin sodium 60mg subcutaneously once daily. The patient was NPO for 3 days and was also monitored for sudden fall in blood pressure, decreased urine output, and fever spikes. On follow-up after 7 days, the patient's condition was significantly improving. The patient was discharged on day 8, with oral antibiotics and analgesics for 5 days, and protein powder for a month.

## Discussion

The term "Gossypiboma" is derived from the Latin word "gossypium," meaning "cotton," and "boma," meaning "concealment." It is a rare but serious and avoidable complication of surgical procedures, involving the retention of a foreign body (RFB) like surgical sponges, which are the most common RFB (80%). This phenomenon was first reported in 1884 by Wilson [2]. The incidence of Gossypiboma is 0.01%–0.001%, making it a very rare but certainly an avoidable complication in almost all surgeries [3]. Risk factors include emergency procedures with heavy blood loss, change of scrub nurse, long duration of surgeries, and obese patients. The most commonly involved areas include the abdomen (46%), followed by the thoracic cavity (23%) [4].

The pathogenesis is due to either an exudative inflammatory response or a milder fibrinous response by the RFB. The exudate response is seen in individuals with a higher antigenic response towards the RFB, eventually leading to an abscess formation around it. As the pressure increases, the abscess ruptures towards its weaker wall, which is commonly the intestinal wall. This further leads to a fistula and eventually pushes the sponge partially into the intestine. In addition, peristaltic waves can also cause the sponge to be withdrawn completely into the lumen of the intestine. Once inside the lumen, it may pass out unnoticed or may lead to obstruction if lodged in the narrowest part. In the latter fibrinous response, the RFB is encapsulated, forming a calcified mass. Migration of the RFB in fibrinous response is rarely seen.

The most common clinical features include pain (73.8%), followed by a palpable mass, vomiting, and fever. Around 0.79% of the cases are asymptomatic. These cases are frequently seen in gynecological surgeries (41.2%) than in abdominal surgeries (35.7%). In India, Gossypiboma is more commonly seen in females and has a median time of discovery of 1225.6 days [5].

Radiological imaging is crucial in the diagnosis of Gossypiboma. Due to variable characteristics, they are more often misinterpreted to be hematomas,

granulomatous lesions, or neoplastic proliferation. Gossypiboma in USG (ultra sonogram) is seen as a whorl-like characteristic pattern, hyper-reflective echo with a hypoechoic rim with strong posterior acoustic shadowing. In CT Scan (Computed Tomography), the most characteristic findings include a mottled, bubbly gas shadows and spongiform pattern [6].

Gossypibomas are managed by an urgent removal of the RFB through an open approach, however, minimally invasive techniques can also be attempted based on the location and size of the RFB. However, endoscopic management of RFB is not recommended in suspected transmural migration of RFB [7].

Gossypibomas not only affect the patient's post-operative healing but also have a significant impact on the career of the surgeon who caused the retention of the foreign body in the patient. Depending on the country, gossypibomas are considered a case of medical negligence or criminal offense, with the case being dealt with similarly to assault or personal injury. In India, the surgeon will usually be prosecuted under Section 304A of IPC (causing the death of any person by doing any rash or negligent act that does not amount to culpable homicide), which is punishable up to 2 years of imprisonment. They could also be prosecuted under Section 336-338 of IPC [1].

Although Gossypibomas are a feared complication, they can be prevented by incorporating a multidisciplinary approach, which includes:

- a) Standardizing the counting procedure - ensuring a correct count of sponges and other materials at the start of the operation and before the closure of the site being operated on.
- b) Utilizing surgical sponges with radiopaque markers, which can be easily detected on imaging modalities like X-Rays.
- c) Enhancing communication among surgeons, nurses, and technicians, and increasing awareness of the location and number of surgical sponges used.
- d) Incorporating technologies such as RFID (Radiofrequency Identification) tagging and barcode scanning of surgical sponges can reduce the risk of Retained Foreign Bodies (RFB).

## References

1. Biswas RS, Ganguly S, Saha ML, Saha S, Mukherjee S, Ayaz A. Gossypiboma and surgeon- current medicolegal aspect - a review. *Indian J Surg.* 2012 Aug;74(4):318-22. <https://doi.org/10.1007/s12262-012-0446-3>. Epub 2012 Mar 27. PMID: 23904722; PMCID: PMC3444596.
2. Lauwers, P., Van Hee, R. Intraoperative Gossypibomas: The Need to Count Sponges. *World J. Surg.* 24, 521-527 (2000). <https://doi.org/10.1007/s002689910084>
3. Patial T, Thakur V, Vijhay Ganesun N, Sharma M. Gossypibomas in India - A systematic literature review.

- J Postgrad Med. 2017 Jan-Mar;63(1):36-41. <https://doi.org/10.4103/0022-3859.198153>. PMID: 28079043; PMCID: PMC5394815.
4. Lincourt AE, Harrell A, Cristiano J, Sechrist C, Kercher K, Heniford BT. Retained foreign bodies after surgery. J Surg Res. 2007 Apr;138(2):170-4. <https://doi.org/10.1016/j.jss.2006.08.001>. Epub 2007 Feb 1. PMID: 17275034.
  5. Patial T, Thakur V, Vijhay Ganesun N, Sharma M. Gossypibomas in India - A systematic literature review. J Postgrad Med. 2017 Jan-Mar;63(1):36-41. <https://doi.org/10.4103/0022-3859.198153>. PMID: 28079043; PMCID: PMC5394815.
  6. Pole G, Thomas B. A Pictorial Review of the Many Faces of Gossypiboma - Observations in 6 Cases. Pol J Radiol. 2017 Aug 1;82:418-421. <https://doi.org/10.12659/PJR.900745>. PMID: 28819464; PMCID: PMC5549714.
  7. Ryan G, Kawka M, Gnananandan J, Yip V. Presentation and surgical management of a gossypiboma presenting with small bowel obstruction. Clin J Gastroenterol. 2021 Aug;14(4):1067-1070. doi: [10.1007/s12328-021-01400-y](https://doi.org/10.1007/s12328-021-01400-y). Epub 2021 Mar 31. PMID: 33788165; PMCID: PMC8298332.