

Phantom Tumor of the Lung

Ali Ghorbani-Abdeghah¹, Reza Ershadi², Amir Reza Radmard³,
Keivan Gohari-Moghadam⁴, Abbas Sadat-Safavi², Ahmad Tajedin¹, Alireza Bagheri⁵

¹ Department of Surgery, Research Center for Improvement of Surgical Outcomes and Procedures, Shariati Hospital, Tehran University of Medical Sciences, Tehran, Iran

² Department of Surgery, Shariati Hospital, Tehran University of Medical Sciences, Tehran, Iran

³ Department of Radiology, Shariati Hospital, Tehran University of Medical Sciences, Tehran, Iran

⁴ Department of Pulmonary Disease, School of Medicine, Tehran University of Medical Sciences, Tehran, Iran

⁵ Department of Pulmonology, School of Medicine, Shahid Beheshti University of Medical Sciences, Tehran, Iran

Received: 7 Oct. 2014; Received in revised form: 26 Nov. 2014; Accepted: 22 Dec. 2014

Abstract

Background: Localized interlobar effusions in congestive heart failure (phantom or vanishing lung tumor/s) are uncommon but well-known entities.

Case Report: The patient is a 60-year-old male with a history of dyspnea and surgical removal of kidney stone in 1 year ago.

Results: In chest-X-ray prior to the surgery an olive-shaped homogenous density, with a size of 30 mm × 20 mm in the right lung have been detected. Computed tomography (CT) scan has been performed, and a homogenous mass with a well-delineated border in major fissure of the right lung and mediastinal lymphadenopathy had been detected. Serial CT scans revealed mass enlargement. In Ct guided, Transthoracic biopsy fluid collection along the major fissure of the right lung had been detected. Biopsy of mediastinal lymph node silicoanthracotic changes with focal hyaline fibrosis had been shown.

Conclusions: The diagnosis of the phantom tumor must be considered in any patient with congestive heart failure and lung mass. In this patient, there was no history of congestive heart failure which shows that phantom tumor could happen in non-chronic heart failure patients. Although the accurate diagnosis of the phantom tumor with imaging modalities in patients without congestive heart failure is very difficult but at least this diagnosis must be considered in a patient with a lung mass in the major fissure of the lungs.

© 2015 Tehran University of Medical Sciences. All rights reserved.

Citation: Ghorbani-Abdeghah A, Ershadi R, Radmard AR, Gohari-Moghadam K, Sadat-Safavi A, Tajedin A, et al. **Phantom Tumor of the Lung.** *Acad J Surg*, 2015; 2(3-4): 66-9.

Keywords: Heart failure, Lung diseases, Lung neoplasms, Phantoms, Imaging, Pleural effusion, Treatment outcome

Introduction

Phantom or vanishing tumor stands for a localized transudative interlobar pleural fluid collection in congestive heart failure. The name originates from its frequent resemblance to a tumor on the chest-X-ray (CXR) and from its tendency to vanish after appropriate management of heart failure.

Case Report

A 60-year-old male with a history of surgical removal of a left kidney stone 1 year ago and history of exertional dyspnea and hypertension from 1 year and several years ago, respectively; who were treated with Amlodipine,

Losartan, and Metoral. In the CXR prior to surgery in 1 year ago a mass in the right lung were detected. Physical examination was normal. Respiratory rate, heart rate, and blood pressure were 32/minutes, 90/minutes and 130/85 mmHg, respectively.

Forced expiratory volume in 1 second was 2.42 L (86% predicted) and forced vital capacity was 3.59 L (84% predicted) in spirometry. Echocardiography revealed mild aortic insufficiency, tricuspid regurgitation, and concentric left ventricular hypertrophy with an ejection fraction of 50-55%. In chest computed tomography (CT) scan (Figure 1) a homogenous 29 mm × 25 mm mass with well-delineated borders (22 HU) in major fissure of the right lung and mediastinal lymphadenopathy was detected. In follow-up CT scans which had been performed at 6

Corresponding Author: Ali Ghorbani Abdeghah

Department of Surgery, 3rd floor, Shariati Hospital, North Kargar Street, 1411713135 Tehran, Iran.

Tel: +98 21 84902450/Fax: +98 2188359109, E-mail: al-ghorbani@sina.tums.ac.ir

months intervals (Figures 2-4) increase in the size of tumor to 44 × 29 and 46 × 35 were detected, respectively. Transthoracic needle biopsy had been performed, which transudative fluid aspirated. In surgical exploration, loculated pleural effusion in the major fissure of the right lung and mediastinal lymph nodes has been seen. Analysis result of the fluid was in concordance with transudative effusion. Pathologic evaluation of the lymph nodes showed silicoanthracotic changes with focal hyaline and fragments of striated muscles. As you see the follow-up CT scan 18 months after the operation is normal (Figures 5).

Discussion

Localized interlobar effusions in congestive heart failure (phantom or vanishing lung tumor/s) are uncommon but well-known entities (1-3). Due to the small number of reported cases, the incidence is difficult to estimate. In

1928, Stewart was the first one to report this entity as “interlobar hydrothorax (4).” Phantom tumors predominantly occur in men in the right hemithorax, with three-quarters of the reported cases within the right transverse fissure and less frequently within the oblique fissure. Simultaneous occurrences in both fissures were reported in about one-fifth of cases while in the left hemithorax were described only sporadically (5). A key role in their pathogenesis, as assumed, is related to adhesions and obliteration of the pleural space around the edge of the fissure due to pleuritis. In such setting, phantom tumors arise whenever the transudation from the pulmonary vascular space exceeds resorptive ability of the pleural lymphatics. However, this atypical intrafissural distribution of pleural effusions can also be explained by local increase in elastic recoil by adjacent, partially atelectatic lung that yields a “suction cup” effect and favors loculation of liquid even in the absence of pleural adhesions (6,7).

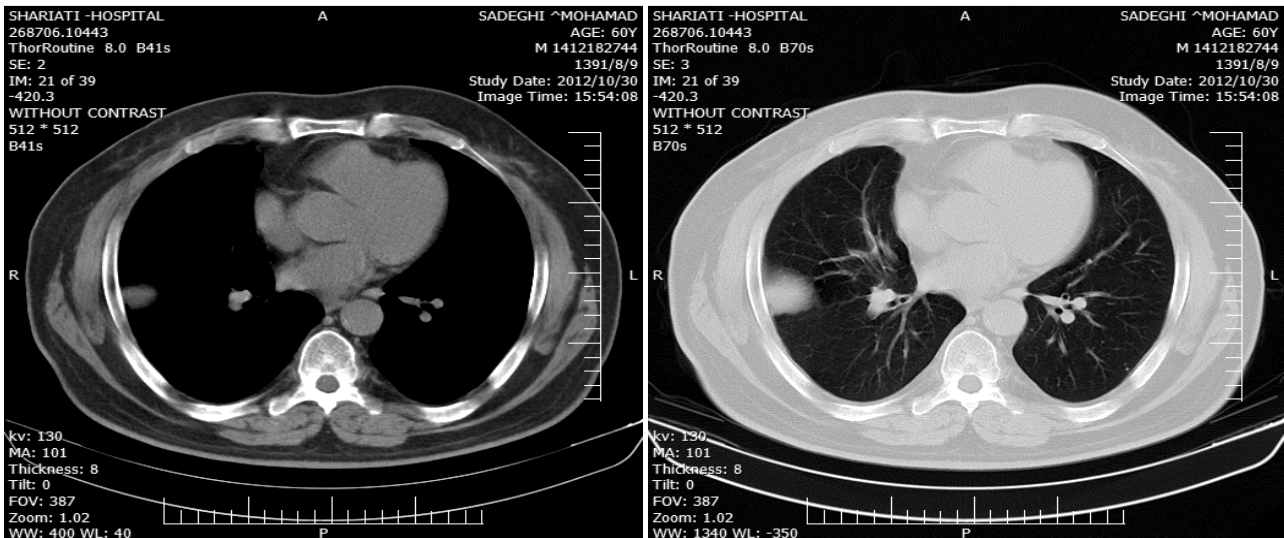


Figure 1. Thoracic computed tomography showing homogeneous, sharply demarcated mass like lesion along the major fissure of right lung

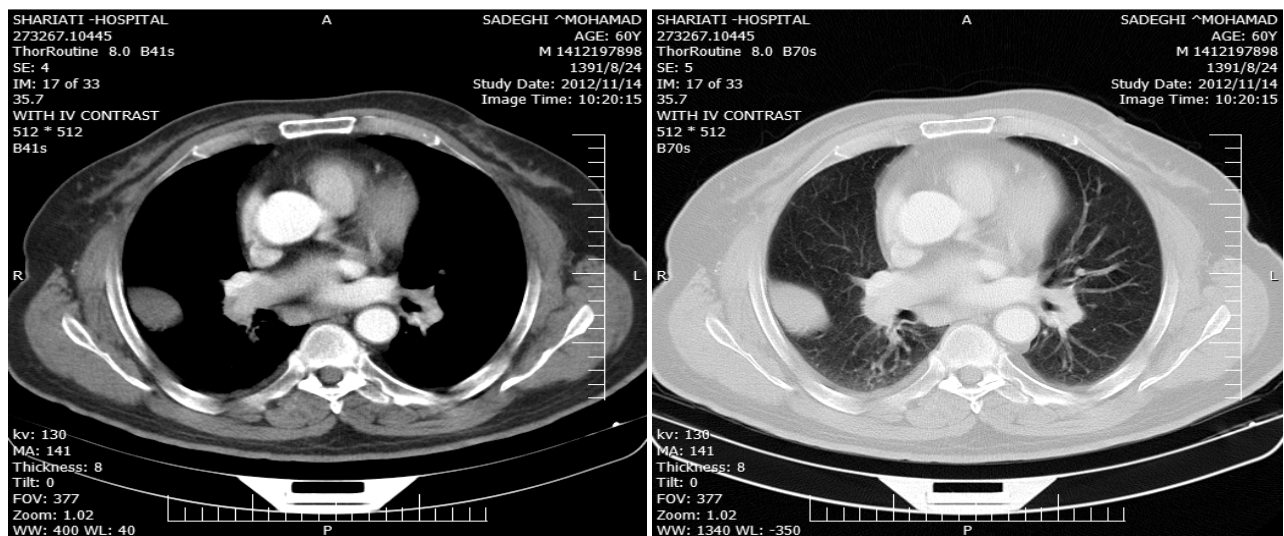


Figure 2. Follow-up computed tomography scans 15 days later

Phantom Tumor of the Lung

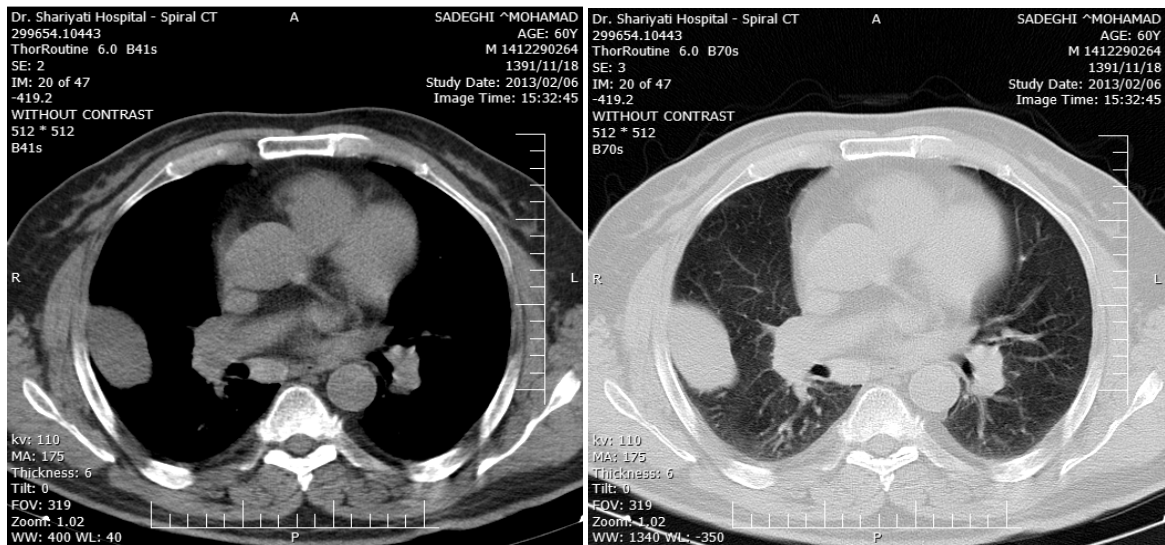


Figure 3. Follow-up computed tomography scans 2 months later

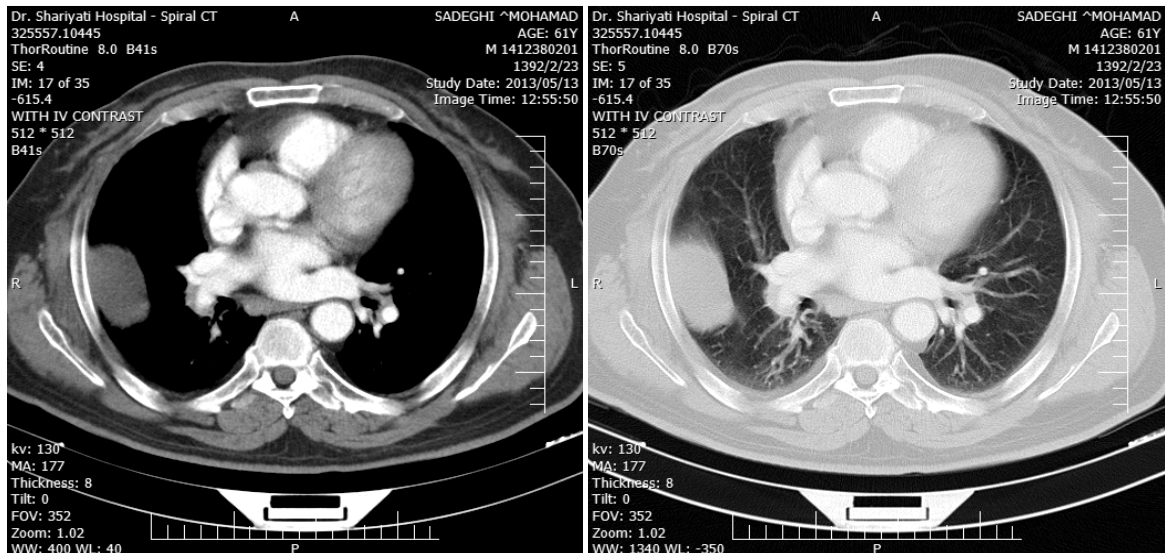


Figure 4. Follow-up computed tomography scans 6 months later

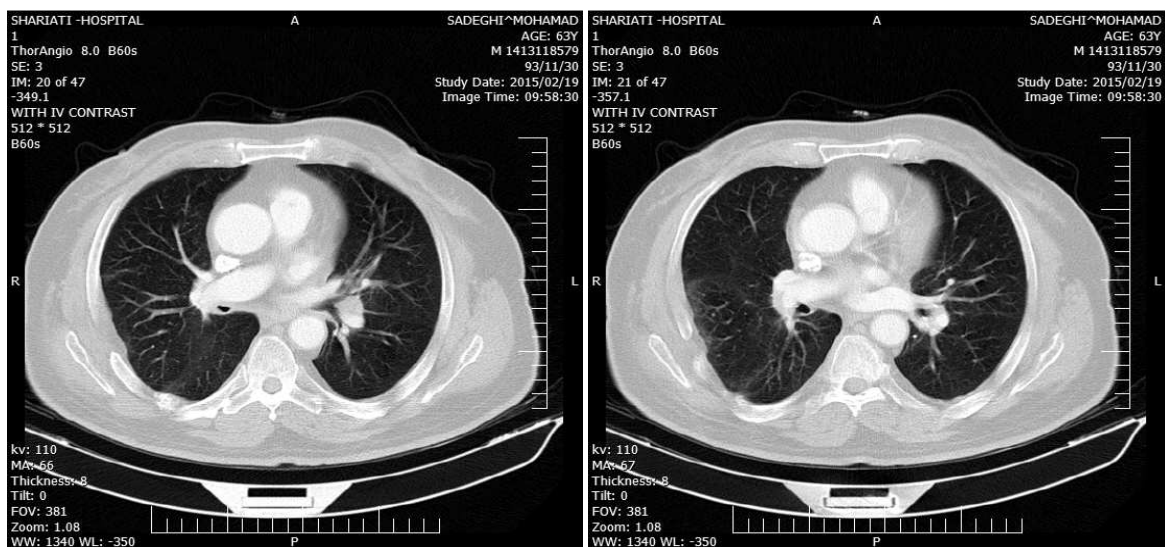

Figure 5. Follow-up computed tomography scan 18 months after operation

The right-sided predilection of the phantom tumor is best explained by the greater hydrostatic pressure existing on this side in comparison with left in congestive heart failure which results in impaired venous and lymphatic drainage causing loculation of fluid (8). The differential diagnosis of loculated pleural effusions within the fissure includes the following: transudates due to the left ventricular failure or renal failure, exudates (parapneumonic pleural effusions, malignant pleural effusions, and benign asbestos-related pleural effusions), and hemothorax, chylothorax, and fibrous tumors originating from the visceral pleura of the interlobar fissure (9).

Conclusion

The diagnosis of the phantom tumor must be considered in any patient with congestive heart failure and lung mass. Although phantom tumors disappear with proper treatment (i.e., diuretics and fluid restriction) but in this patient there was no history of congestive heart failure which shows that phantom tumor could happen in non-chronic heart failure patients. Although the accurate diagnosis of phantom tumor with imaging modalities in patients without congestive heart failure is very difficult but at least this diagnosis must be considered in a patient with a lung mass in the major fissure of the lungs.

Acknowledgments

None.

References

1. Gefter W, Boucot K, Marshall E. Localized interlobar effusion in congestive heart failure vanishing tumor of the lung. *Circulation*. 1950; 11: 336-43.
2. Millard CE. Vanishing or phantom tumor of the lung; localized interlobar effusion in congestive heart failure. *Chest*. 1971; 59(6): 675-77.
3. Oliveira E, Manuel P, Alexandre J, Girao F. Phantom tumour of the lung. *Lancet*. 2012; 380(9858): 2028.
4. Bedford DE, Lovibond JL. Hydrothorax in heart failure. *Br Heart J*. 1941; 3(2): 93-111.
5. Buch KP, Morehead RS. Multiple left-sided vanishing tumors. *Chest*. 2000; 118(5): 1486-9.
6. Fleischner FG. Atypical arrangement of free pleural effusion. *Radiologic Clinics of North America*. 1963; 1: 347-62.
7. Stark P, Leung A. Effects of lobar atelectasis on the distribution of pleural effusion and pneumothorax. *J Thorac Imaging*. 1996; 11(2): 145-9.
8. Rabinowitz JG, Kongtawng T. Loculated interlobar air-fluid collection in congestive heart failure. *Chest*. 1978; 74(6): 681-3.
9. Haus BM, Stark P, Shofer SL, Kushner WG. Massive pulmonary pseudotumor. *Chest*. 2003; 124(2): 758-60.