

## Symptomatic Müllerian Duct Cyst in a Male Adult: A Rare Case Report

Shahram Shabaninia<sup>1</sup>, Seyed Reza Yahyazadeh<sup>1</sup>

<sup>1</sup>Assistant Professor, Department of Urology, School of Medicine, Tehran University of Medical Sciences, Tehran, Iran

Received: 23 Jan. 2016; Received in revised form: 17 Aug. 2016; Accepted: 28 Oct. 2016

### Abstract

**Background:** Müllerian duct cyst is an uncommon congenital anomaly. It is usually small and asymptomatic. A rare case of this entity with symptoms of ejaculatory duct obstruction such as hematospermia and secondary infertility is presented here.

**Case Report:** A 39-year-old male presented with complaints of pain in the lower abdomen, dysuria, frequency, and hematospermia for the last 2 years. He also suffered from secondary infertility with a 9-year-old son. Imaging studies showed a large cystic midline lesion right behind the bladder and also bilateral dilated ejaculatory ducts. The patient underwent a transurethral drainage. The prostatic urethra was resected using a 26 Fr resection loop proximal to the verumontanum and a capacious cystic structure opened, and finally two dilated ejaculatory duct openings were seen. On follow-up, a significant improvement of symptoms and semen quality was achieved after surgery.

**Conclusions:** A high index of suspicion in using advanced imaging modalities is necessary for the diagnosis of this anomaly. Surgical excision of a Müllerian duct cyst may be performed depending on the size and location of the cyst and the presence of clinical symptoms. Transurethral de-roofing of the cyst is effective and safe for the treatment of small Müllerian duct cyst accompanied with ejaculatory duct obstruction.

© 2017 Tehran University of Medical Sciences. All rights reserved.

**Citation:** Shabaninia S, Yahyazadeh SR. **Symptomatic Müllerian Duct Cyst in a Male Adult: A Rare Case Report.** *Acad J Surg*, 2017; 4(1): 24-6.

**Keywords:** Müllerian duct; Cysts; Infertility; Transurethral

### Introduction

Müllerian duct cyst is an uncommon congenital anomaly. It is usually small, asymptomatic, midline, cystic lesion, located behind the superior half of the prostatic urethra and connected to the verumontanum by a thin stalk. Patients diagnosed with Müllerian duct cyst usually do not experience any cyst-related symptoms or ejaculatory-fertility impairment, so treatment only is recommended in symptomatic and infertile patients.

A rare case of this entity with symptoms of ejaculatory duct obstruction such as hematospermia and secondary infertility is presented here.

### Case Report

A 39-year-old male presented with complaints of pain in the lower abdomen, dysuria, frequency, and hematospermia for the last 2 years. He also suffered from secondary infertility with a 9-year-old son. On digital rectal examination, a smooth bulge was palpable in the anterior wall of the rectum above the prostate, and bilateral seminal vesicles and ejaculatory ducts were also palpable.

In two sequential semen analyses, azoospermia and

low-volume ejaculate (0.5 ml or less) were noted.

The patient was subjected to a transrectal ultrasonography (TRUS) which showed a large cystic midline lesion right behind the bladder and also bilateral dilated ejaculatory ducts were noted (Figure 1).

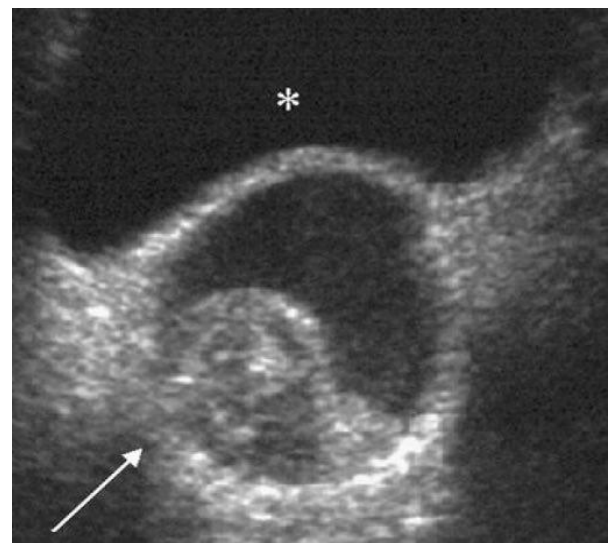


Figure 1. Transrectal ultrasonography study

Pelvic magnetic resonance imaging (MRI) was

**Corresponding Author:** Seyed Reza Yahyazadeh

Department of Urology, School of Medicine, Tehran University of Medical Sciences, Tehran, Iran  
Tel/Fax: +98 21 88633039, E-mail: r.yahyazadeh@gmail.com

performed showing a thick-walled, midline cystic structure associated with the prostate (Figure 2).

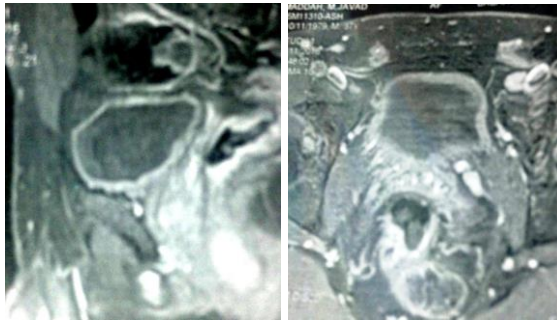


Figure 2. (a and b) Magnetic resonance imaging study

The patient underwent a transurethral drainage. Intraoperatively, there was no evident of urethral connection. The prostatic urethra was resected using a 26 Fr resection loop proximal to the verumontanum and a capacious cystic structure opened. Internally, there was hemorrhagic fluid with the walls of the structure covered in an adherent white fibrotic sloughy tissue.

The cystic content was bluntly enucleated which showed two dilated ejaculatory duct openings (Figure 3).

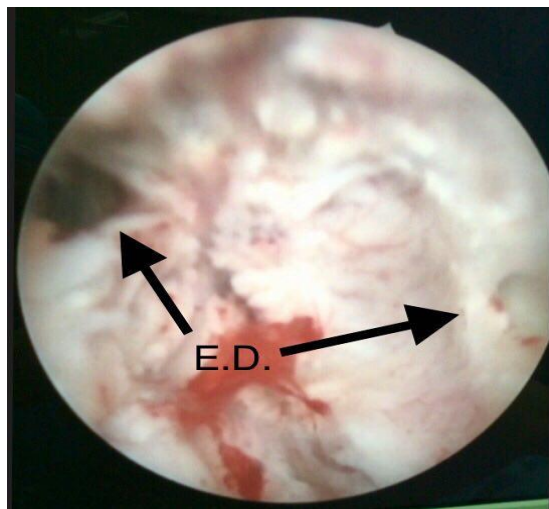


Figure 3. Prostatic Müllerian duct cyst with two dilated ejaculatory duct openings

A significant improvement of semen quality was achieved after surgery and the sperms could be seen. Semen volume of the patient increased after the operation compared with that of before the operation.

## Discussion

Müllerian duct cysts present at the 3<sup>rd</sup> to 4<sup>th</sup> decade. Müllerian duct cysts do not communicate with the prostatic urethra, but are connected to the verumontanum by a thin stalk. Müllerian duct cyst is not typically associated with other congenital

abnormalities of the urinary tracts. Very rarely, these may be associated with ipsilateral renal agenesis (1).

Müllerian duct cysts are round or oval in configuration, often large and extend well above the base of the prostate. A prevalence of 1-5% (2) has been reported for Müllerian duct cysts, but symptomatic presentation is very rare. The clinical presentation is varied, including urinary frequency, urinary urgency, dysuria, urinary obstruction, hematuria, and pelvic pain.

Differential diagnosis of deep pelvic cysts in males includes utricular cysts, seminal vesicle cyst, ejaculatory duct cyst, prostatic cyst or abscess, urachal cyst, bladder diverticulum, hydatid cyst, and intrapelvic neoplasms.

MRI has been reported to be useful in the diagnosis of Müllerian duct cysts by showing signal characterization of the mucus or hemorrhagic cystic component. At MRI, Müllerian duct cysts are usually hypointense on T1-weighted images and hyperintense on T2-weighted images (Figure 4).

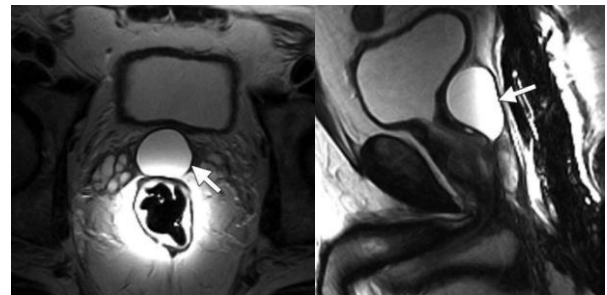


Figure 4. Axial and sagittal T2-weighted magnetic resonance images obtained with an endorectal coil showing a prostatic Müllerian duct cyst in a 42-year-old male

However, they may demonstrate increased signal intensity on both T1- and T2-weighted images, reflecting increased concentration of mucinous material, hemorrhage, or pus (3).

An MRI in this patient would have helped achieve a proper pre-operative diagnosis.

At TRUS, such a lesion manifests as a midline anechoic cystic cavity posterior to the urethra and may extend above the base of the prostate (Figure 5).

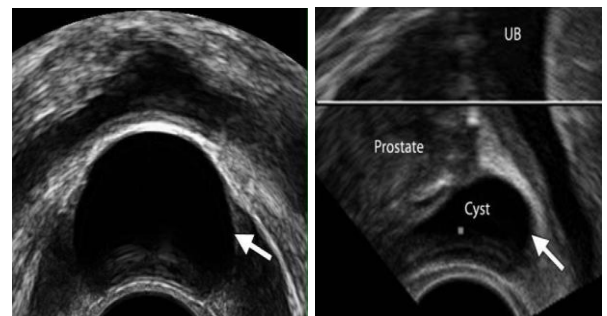


Figure 5. Prostatic Müllerian duct cyst in the same patient as in Figure 4. Axial and sagittal three-dimensional transrectal ultrasonography images showing a midline anechoic cystic lesion between the seminal vesicles and the urinary bladder (UB)

## Symptomatic Müllerian Duct Cyst in a Male Adult

Treatment is indicated in symptomatic individuals to prevent long-term complications. Surgical management of medullary duct cysts is challenging due to their deep location in the pelvic and close relation to important surrounding structures. Surgical excision of a Müllerian duct cyst may be performed depending on the size and location of the cyst and the presence of clinical symptoms (4).

Both open surgical techniques and minimally invasive approaches have been described to treat Müllerian duct remnants. Endoscopic treatment has been limited to unroofing infected and obstructed cysts. For a large pelvic or abdominal cyst, open surgical excision is the treatment of choice (5). Many different open surgical approaches have been described to excise Müllerian duct remnants; recently, laparoscopic- and robot-assisted excisions have been utilized for excising Müllerian duct cysts and remnants.

### Conflict of Interests

Authors have no conflict of interests.

### Acknowledgments

We thank CRCP journal's editors for assistance and comments that greatly improved the manuscript.

### References

1. Ulu EM, Basaran C, Dönmez FY, Güven Z, Güner B, Coskun M. Müllerian duct cyst with ipsilateral renal agenesis: MRI findings. *Marmara Med J* 2009; 22(1): 67-7.
2. Coppens L, Bonnet P, Andrianne R, de Leval J. Adult Mullerian duct or utricle cyst: Clinical significance and therapeutic management of 65 cases. *J Urol* 2002; 167(4): 1740-4.
3. Simpson WL Jr, Rausch DR. Imaging of male infertility: Pictorial review. *AJR Am J Roentgenol* 2009; 192(6 Suppl): S98-107.
4. Parsons RB, Fisher AM, Bar-Chama N, Mitty HA. MR imaging in male infertility. *Radiographics* 1997; 17(3): 627-37.
5. McDermott VG, Meakem TJ 3<sup>rd</sup>, Stolpen AH, Schnell MD. Prostatic and periprostatic cysts: Findings on MR imaging. *AJR Am J Roentgenol* 1995; 164(1): 123-7.